



2010

LEG PROBLEMS AND POWER LINE INTERACTIONS IN THE FLORIDA RESIDENT FLOCK OF WHOOPING CRANES

Jaimie L. Miller
Marilyn G. Spalding
Martin J. Folk

Miller, J. L., M. G. Spalding, and M. J. Folk. 2010. Leg problems and power line interactions in the Florida resident flock of whooping cranes. *Proceedings of the North American Crane Workshop* 11:156-165.

The North American Crane Working Group provides free and open access to articles in Proceedings of the North American Crane Workshop. No additional permission is required for unrestricted use, distribution, or reproduction in any medium, provided that the original work here is properly cited. Visit <http://www.nacwg.org> to download [individual articles](#) or to download or purchase [complete Proceedings](#).

© 2010 North American Crane Working Group

LEG PROBLEMS AND POWER LINE INTERACTIONS IN THE FLORIDA RESIDENT FLOCK OF WHOOPING CRANES

JAIMIE L. MILLER, Department of Infectious Diseases and Pathology, College of Veterinary Medicine, University of Florida, Box 110880, Gainesville, FL 32610, USA

MARILYN G. SPALDING, Department of Infectious Diseases and Pathology, College of Veterinary Medicine, University of Florida, Box 110880, Gainesville, FL 32610, USA

MARTIN J. FOLK, Florida Fish and Wildlife Conservation Commission, 1475 Regal Court, Kissimmee, FL, 34744, USA

Abstract: We retrospectively reviewed a database with over 1,800 health entries from 296 captive-reared whooping cranes (*Grus americana*) released in central Florida and 10 wild-fledged chicks from 1992 to 2007. Fifty percent of the study population ($n = 306$) had 1 or more leg problems that were placed into 4 broad categories: power line interactions ($n = 39$), other trauma ($n = 94$), deformities ($n = 43$), and miscellaneous conditions ($n = 106$). More males ($n = 26$, 67%) had power line interactions than females ($n = 13$, 33%). The majority of these 39 birds died (57%), while the rest recovered from an injury (20%), went missing (7%), or survived with no apparent injury (16%). Twenty-two of the 44 (50%) recorded power line strikes involved the leg-mounted transmitter. Most minor leg problems in the other trauma category were observed at arrival or quarantine examinations; no major injuries occurred as a result of >800 handling or capture events. Birds arriving in Florida with toe deformities, short legs, or a leg rotation had no difference in survival or reproductive value when compared to the general population. All categories except for deformities contained birds with injuries associated with mortality. The most mortality related injuries were a result of power line interactions. Among the 149 birds with leg problems, 44 cranes (29%, 14% of all birds) had injuries sufficient enough to be associated with mortality. Birds that survived leg injuries lived longer than birds with no previous injury prior to death.

PROCEEDINGS OF THE NORTH AMERICAN CRANE WORKSHOP 11:156-165

Key words: deformities, Florida, *Grus americana*, leg injuries, monofilament line, power lines, radio transmitters, whooping cranes.

The reintroduced resident flock of whooping cranes (*Grus americana*) in Florida was established in an attempt to satisfy a goal of the species recovery plan (CWS and USFWS 2007). Four breeding centers were involved with captive rearing cranes for release into this flock (Nesbitt et al. 1997). Problems involving the legs are a continual concern for captive-reared cranes (Wellington et al. 1996), but their importance following release is not known. Kelley and Hartup (2008) identified potential risk factors for leg and toe deformities, including rearing method, egg source, egg laying order, and relative weight change during the first and second weeks of age. Here we analyzed a database of health records from 306 wild-fledged and captive-reared whooping cranes to determine the prevalence of leg problems and power line interactions, and their significance to health and survival in the wild. We also evaluated the survival and reproduction of birds released with pre-existing leg and toe deformities.

METHODS

Our study population consisted of 306 whooping

cranes: 296 birds reared in captivity and released into the wild at 6 to 10 months of age (155 males and 141 females) and 10 wild-fledged birds (2 males and 8 females) from 1992 to 2007. Cranes were reared in captivity at Patuxent Wildlife Research Center (PWRC), Laurel, Maryland; International Crane Foundation (ICF), Baraboo, Wisconsin; the Calgary Zoo, Calgary, Alberta; and the San Antonio Zoo, San Antonio, Texas. Captive-reared birds were examined upon arrival in Florida and a leg-mounted transmitter was attached to either the left or right leg to track the birds for further monitoring. After a pre-release examination 2 weeks after arrival, birds were soft-released (Nesbitt et al. 1997) in 3 central Florida counties (Lake, Osceola, and Polk). The birds were frequently monitored to obtain location, health status, breeding status, and to observe behavior. We captured birds by 10 methods in order to replace transmitters and gather health data (Folk et al. 2005). All relevant health data were stored in a database which contained over 1,800 records of field observations, captures, and necropsy reports.

We searched the database for key words indicating

possible leg problems or power line interactions. All conditions noted at the arrival examination and thereafter were considered. Birds <1 year of age were considered chicks, while birds 1 to <3 years of age were subadults and those ≥ 3 years of age were adults. Conditions were placed into 4 broad categories: power line interactions, other traumatic injuries, deformities, and miscellaneous conditions. Birds could be placed in multiple categories based on the problems diagnosed and were included in each category total but were only counted once for the total injured population. Percentages refer to the percent of total population unless stated otherwise.

We defined a power line interaction as either direct evidence that a bird hit the power line, such as finding a dead or injured bird or its transmitter under a power line, or when a bird died from other causes such as predation, but was believed to have been previously injured from striking a power line in the area. For example, a bird with a broken wing within sight of a power line that was killed by a bobcat several days later was considered as a power line interaction.

Other traumatic injuries included leg dangle (leg is dropped from normal flight position), hip dislocation, leg fracture, fence and vehicular collision, lameness, monofilament line entanglement, and/or wounds. Wounds included abrasions, lacerations, and sores. Injuries sustained during capture or handling were also included in this category.

Deformities included toe deformities, short legs, rotated tarsometatarsus, or any combination of the 3 that were present upon arrival in Florida. An ANOVA test was used to determine the effects of developmental deformities on survival and reproduction for birds ≥ 3 years of age using age at death or age in 2007 for surviving birds and the reproductive value of the bird. The reproductive value was calculated as per Spalding *et al.* (2010).

Miscellaneous conditions included birds with defects of the integument (calluses, cracked skin, crusts, dermatitis, dry skin, hyperemia, scabs, scars, sloughing skin, and avulsed skin), swelling (arthritis, bruises, cellulitis, edema, hemorrhage, and myositis, as well as generalized swelling), and miscellaneous toe problems (lost or missing toes or toenail injuries, pododermatitis, chondroma, and undiagnosed nodules).

An injury was considered related to death if it directly led to mortality or if it predisposed the bird to

predation. If the injury did not meet these criteria, it was considered to be unrelated to mortality. A Kaplan-Meier survival analysis was used to gauge the survival of birds with injuries to birds with no recorded injury. An ANOVA test was used to evaluate leg problems and the source (PWRC, ICF, other, or wild) and rearing method among birds reared in isolation, by surrogate parents, as a combination of the 2, or by wild parents (Nagendran *et al.* 1996).

RESULTS

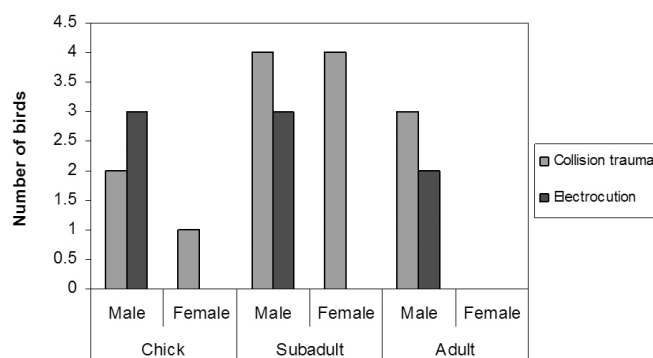
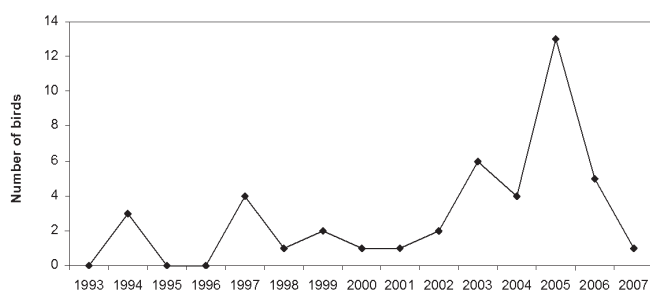
We determined 50% (154/306 birds; 78 males, 76 females) of the flock had 1 or more leg problems. We categorized these as power line interactions (39/306, 13% of total population), other trauma (94/306, 31%), deformities (43/306, 14%), and miscellaneous conditions (106/306, 35%).

Power Line Interactions

Thirty-nine whooping cranes had 44 power line interactions (Table 1). More males ($n = 26$, 67%) than females ($n = 13$, 33%) collided with power lines. The majority of these 39 birds died (57%), while the rest recovered from an injury (20%), went missing (7%), or survived with no apparent injury (16%). Four birds had multiple (2 to 3) power line interactions. Two males and 1 female died as a result of their second interaction and another female was still alive in 2007 after 3 interactions. The transmitter or the transmitted leg was involved in 22 (50%) of the 44 individual power line interactions. Seventeen cases involved the transmitter being separated from the leg. The transmitter was involved twice for 1 bird, the first encounter causing a wound on the tarsometatarsus of the transmitted leg and the second causing lameness of the transmitted leg. All 8 instances of electrocution involved male birds; 3 were chicks, 3 were subadults, and 2 were adults (Fig. 1). Most of the female power line mortality was among subadult birds; in fact, no adult females died as a result of power line interaction. Five birds remained alive in 2007 following interactions with power lines. These birds include 2 males with no injuries, 2 females with temporary wing injuries, and a female with 3 power line interactions (1 wound on the tarsometatarsus of the transmitted leg, short-term lameness of the non-transmitted leg, and

Table 1. Summary of whooping crane power line interactions in central Florida, 1992-2007.

Power line interaction	Total birds	% of total population	Sex		Age			Total instances
			M	F	Chick	Subadult	Adult	
Collision trauma	14	5	9	5	3 ¹¹	8 ¹³	3 ¹¹	14
Electrocution	8	3	8	0	3	3	2 ¹¹	8
Survived uninjured	7	2	5	2	0	3 ¹³	4 ¹⁴	7
Lameness	6	2	3	3	2 ¹¹	1 ¹¹	3 ¹²	6
Missing	3	1	2	1	1 ¹¹	2 ¹²	0	3
Wing injury	3	1	1	2	0	2	1	3
Leg fracture	2	1	1	1	0	1	1 ¹¹	2
Leg wound	1	<1	0	1	0	0	1 ¹¹	1
TOTAL	39 ^a	13	26	13	9	20	15	44

^a Birds with multiple conditions were only counted once.¹ⁿ Number of birds with injuries involving the transmitter.**Figure 1. Gender and age of whooping cranes that died from trauma or electrocution when colliding with power lines in central Florida, 1992-2007.****Figure 2. Number of whooping crane power line interactions in central Florida, 1993-2007.**

short-term lameness of the transmitted leg).

An increase in the number of power line strikes occurred from 2003 to 2005 (Fig. 2). There were 23 interactions during those 3 years; 14 interactions were recorded the previous 10 years (1993-2002). There were 13 interactions in Lake and Sumter counties from

the same power line, resulting in 6 dead or missing birds from 2003 to 2005. These all involved transmission lines (>115 kV) located between roosting and foraging sites. The increase was attributed to birds roosting and foraging on opposite sides of power lines based upon observations of sites used and flight patterns.

Other Trauma

Seventy-two whooping cranes had other traumatic injuries (Table 2). Two female birds observed dangling a leg while in flight (Fig. 3) were still alive in 2007, while the others either died from bobcat predation or went missing within a few months after injury. No cause for these leg deviations were found at post mortem examination. One of the surviving birds no longer had a leg dangle but did have a recurring limp in the opposite leg. The other bird's condition remained unchanged.

One (1%) female bird suffered a hip dislocation after getting caught in a fence as a subadult. The hip displacement resolved in transit to the University of Florida Veterinary Medical Center (VMC) and this bird was released after a short period of treatment while a laceration healed. This bird sustained no other injuries until 10, 12, and 13 years of age, when a right digit 2 curl, lameness, and left digit 3 swelling, respectively, were observed. This bird was alive in 2007 and fledged 2 chicks.

Nine (3%) whooping cranes were recorded with leg fractures (Table 3). Five of the 6 (83%) single leg fractures involved the transmitted leg. Of 5 birds with leg fractures, 3 that were hospitalized and 1 left alone in the

Table 2. Summary of whooping cranes with other (non-power line) traumas in central Florida, 1992-2007.

Other trauma	Total birds	% of total population	Sex		Age			Total instances
			M	F	Chick	Subadult	Adult	
Wounds	50	16	21	29	40	7	6	53
Lacerations	29	9	13	16	20 ^{t1}	5	5 ^{c1,t2}	30
Abrasions	20	7	8	12	20	2	1 ^{t1}	23
Lameness	21	7	10	11	4 ^{t4}	9 ^{t4}	10 ^{t4}	23
Leg fracture	9	3	6	3	1 ^{t1}	4 ^{t2}	4 ^{t2}	9
Fence and vehicular collisions	7	2	2	5	0	3	4 ^{t1}	7
Fence collision	5	2	0	5	0	2	3	5
Vehicular collision	2	1	2	0	0	1	1	2
Leg dangle	6	2	2	4	3 ^{t2}	1	2	6
Monofilament line entanglement	5	2	0	5	1 ^{t1}	3	2	6
Hip dislocation	1	<1	0	1	0	1	0	1
TOTAL	70 ^a	23	31	39	50	28	27	105

^a Birds with multiple conditions were only counted once.^{cn} Number of birds with a capture-related injury.^{tn} Number of birds with an injury involving the transmitter.**Figure 3. A whooping crane with a leg deviating from normal flight position.**

wild died, while 1 that remained in the wild without intervention survived and reproduced. Seven (2%) whooping cranes have collided with either a vehicle or a fence (Table 4). In addition there were other cases of fence collision or entanglement that did not involve injury to the legs. Twenty-one (7%) whooping cranes were observed in the field with lameness (Table 5). All 5 (2%) whooping cranes reported with monofilament line entanglement were females (Fig. 4). Aside from the injuries listed in Table 6, all 5 birds recovered from the monofilament line entanglement.

Most of the wounds observed were in chicks (10 at the arrival examination and 27 at pre-release examination); remaining wounds occurred in 6 subadults and 6 adults.

Table 3. Details of whooping crane leg fractures in central Florida, 1992-2007.

Sex	Age	Fracture location	Fracture cause	Outcome
Female	Subadult	Bilateral tarsometatarsus ^t	Power line	Euthanized
Female	Subadult	Left tibiotarsus ^t	Power line	Died-corn aspiration in captivity for fracture repair
Female	Adult	Bilateral femurs ^t	Struck by golf ball	Died-anesthesia complications
Male	Chick	Right tarsometatarsus ^t	Unknown	Found dead
Male	Subadult	Right tarsometatarsus ^t	Entangled in cow feeder	Died-anesthesia complications
Male	Subadult	Bilateral tarsometatarsus ^t	Vehicular collision	Euthanized
Male	Adult	Left tibiotarsus ^t	Unknown	Bobcat predation 21 days later
Male	Adult	Left tarsometatarsus	Unknown	Healed with bones overriding and fledged 1 chick
Male	Adult	Bilateral femurs ^t	Unknown	Found dead

^t Transmitter leg involved.

Table 4. Details of whooping crane fence and vehicle collisions in central Florida, 1992-2007.

Sex	Age	Object of collision	Outcome
Female	Subadult	Fence	Hip dislocation (resolved), fledged 2 chicks
Female	Subadult	Fence	Found dead near fence
Female	Adult	Fence	Bird uninjured, transmitter found near fence
Female	Adult	Fence	Found dead near fence
Female	Adult	Fence	Found dead near fence
Male	Subadult	Vehicle	Euthanized due to bilateral leg fractures
Male	Adult	Vehicle	Found dead in middle of highway with multiple fractures

Table 5. Details of whooping crane lameness in central Florida, 1992-2007.

Sex	Age	Leg	Lameness cause	Outcome
Female	Chick	Right ^t	Power line interaction	Died 1 year later from power line collision
Female	Chick	Right ^t	Unknown	Still alive
Female	Subadult	Right ^t	Monofilament line entanglement	Lameness resolved
Female	Subadult	Right ^t	Unknown	Bobcat predation 2 days later
Female	Subadult	Left ^t	Monofilament line entanglement	Lameness resolved
Female	Subadult	Left ^t	Unknown	Found dead
Female	Subadult	Left	Unknown	Bobcat predation >5 years later
Female ^a	Adult	Left ^t	Monofilament line entanglement	Lameness resolved
Female	Adult	Left ^t	Unknown	Lost transmitter, still lame (2007)
Female	Adult	Left ^t	Power line interaction	Died-corn aspiration in captivity for leg fracture repair
Female ^a	Adult	Left ^t	Power line interaction	Still alive
Female	Adult	Left	Unknown	Still alive
Female ^a	Adult	Right	Power line interaction	Still alive
Male	Chick	Left ^t	Unknown	Lameness resolved
Male	Chick	Left ^t	Power line interaction	Lameness resolved
Male	Subadult	Right ^t	Unknown	Bobcat predation 20 days later
Male	Subadult	Left ^t	Power line interaction	Went missing >4 years later
Male	Subadult	Right	Unknown	Lameness resolved
Male	Subadult	Left ^t	Unknown	Still alive
Male	Adult	Left ^t	Power line interaction	Bobcat predation 21 days later
Male	Adult	Left	Re-injured healed fractured leg	Lameness resolved, fledged 1 chick
Male	Adult	Left ^t	Unknown - chip out of transmitter band	Died ~2.5 years later from EEE
Male	Adult	Right	Unknown	Went missing 3 months later

^a Same bird with 3 separate instances of lameness.^t Transmitter leg involved.

The location of these wounds varied and some birds had multiple wounds noted. One adult female sustained a laceration on a toe during capture. The transmitter was responsible for 4 instances of minor leg wounds.

There were 9 capture or handling related injuries. One male bird and 2 wild-fledged female chicks had an avulsed toenail during hand captures. Another adult female had a laceration on a toe from the netting used in a clap trap capture. Five chicks (3 males and 2 females) had torn toenails due to handling prior to release. Three birds were still alive in 2007 including a wild-fledged chick.

The remaining birds died due to causes not associated with either their capture or handling injury.

Deformities

The deformities category included 43 (14%) chicks with toe deformities ($n = 28$), short legs ($n = 11$), and/or rotated tarsometatarsus ($n = 12$) found at either the arrival or pre-release examinations (Table 7). Although whooping cranes with toe deformities tended to have a lower index of reproductive value than the general



Figure 4. A wild-fledged whooping crane with monofilament line entanglement that included the antenna of the transmitter and caused swelling of the foot (A); close up of entanglement (B).

Table 6. Details of whooping crane monofilament line entanglement in central Florida, 1992-2007.

Sex	Age	Entanglement location	Outcome
Female	Chick	Left leg [†] and foot	Swelling and lameness (both resolved)
Female	Subadult	Right tarsometatarsus [†]	Swelling and lameness (both resolved)
Female ^a	Subadult	Left tarsometatarsus [†]	Swelling and lameness (both resolved), lost 2/3 left hallux
Female	Subadult	Left tarsometatarsus	Swelling (resolved)
Female ^a	Adult	Left leg [†]	Swelling (resolved), scarring on leg
Female	Adult	Left tibiotarsus	Swelling (resolved)

^a Same bird with 2 separate instances of monofilament line entanglement.

[†] Transmitter leg involved.

Table 7. Summary of whooping crane deformities in central Florida, 1992-2007.

Power line condition	Total birds	% of total population	Sex		Age			Total instances
			M	F	Chick	Subadult	Adult	
Toe deformities	36	12	17	19	31	3	2	36
Rotated tarsometatarsus	12	4	3	9	9	1	0	12
Short legs	10	3	2	8	12	0	0	10
TOTAL	50 ^a	16	20	30	52	4	2	58

^a Birds with multiple conditions were only counted once.

population, there was no statistical difference ($P > 0.05$). Those with short legs or leg rotations also did not differ from the reproductive value of the general population ($P > 0.05$). Overall, birds with leg deformities had no statistical difference of survival rate than the general population ($P > 0.05$).

Miscellaneous Conditions

Eighty-five (28%) whooping cranes were observed

with miscellaneous conditions (Table 8). Calluses, scabs, and scars were the most reported defect in the integument and were most often a minor injury due to the transmitter wearing on the skin of the hock. Pododermatitis was found in 4 (1%) chicks, prior to their release. Two (1%) male whooping cranes have been seen with chondromas (cartilage tumors). One wild-fledged chick with an 8-mm-round chondroma on the tarsus was partially biopsied and the remaining mass regressed to a small scar within 2 years. The other chondroma was a 1×1×1 cm

Table 8. Summary of whooping crane miscellaneous conditions in central Florida, 1992-2007.

Condition	Total birds	% of total population	Sex		Age			Total instances
			M	F	Chick	Subadult	Adult	
Swelling	40	13	16	24	31	6	13	50
Generalized swelling	33	11	13	20	23 ^{b1,m1,t3}	5 ^{m1,t3}	12 ^{b1,m3,t2}	40
Bruises	3	1	2	1	3	0	0	3
Cellulitis	3	1	2	1	2 ^{t1}	0	1	3
Edema	2	1	1	1	1 ^{b1}	1 ^{m1}	0	2
Arthritis	1	<1	0	1	1	0	0	1
Myositis	1	<1	0	1	1	0	0	1
Defects of integument	44	14	23	21	30	4	18	52
Calluses	15	5	10	15	1 ^{b1}	1 ^{t1}	13 ^{t13}	15
Scabs	9	3	3	6	8	0	1	9
Scars	9	3	3	6	6	0	3	9
Hyperemia	8 ^a	3	4	4	8	0	0	8
Crusts	3	1	2	1	3	0	0	3
Dermatitis	3	1	1	2	1	2	0	3
Sloughing skin	2	1	2	0	2	0	0	2
Avulsed skin	1	<1	0	1	0	0	1	1
Cracked skin	1	<1	0	1	1	0	0	1
Dry skin	1	<1	1	0	0	1	0	1
Miscellaneous toe problems	17	6	9	8	13	1	3	17
Toenail injuries	14	5	7	7	13 ^{c7}	0	1 ^{c1}	14
Lost/missing toes	3	1	2	1	0	1	2	3
Pododermatitis	4	1	2	2	4	0	0	4
Chondroma	2	1	2	0	1	1	0	2
Undiagnosed nodules	2	1	1	1	1	0	2	3
TOTAL	84 ^d	27	41	43	80	12	36	128

^a Six instances of hyperemia found on hips and associated with copulatory mounting.

^{bn} Number of birds with an injury from the aluminum identification band.

^{cn} Number of birds with a capture related injury.

^d Birds with multiple conditions were only counted once.

^{mn} Number of birds with an injury from monofilament line entanglement.

^{tn} Number of birds with an injury involving the transmitter.

raised white nodule with a crusted center found on the tarsus of a subadult male that had been killed by a bobcat. Two (1%) whooping cranes had undiagnosed nodules. A male chick had a proliferative epithelial lesion that resembled avian pox on the right digit 2 at the time of release. A female adult had 2 similar occurrences, 1 lesion on the foot that resolved, and 1 lesion near the hock 4 months later that also resolved.

Injury Relation to Mortality, Source, and Rearing Method

Of the 149 whooping cranes with leg problems and power line interactions, 118 (79%) have died. Forty-four (29%, 14% of total population) had injuries severe enough to be associated with mortality (Fig. 5). These birds were in the following categories: power line

interactions ($n = 28$), other trauma ($n = 15$), and miscellaneous conditions ($n = 1$). Birds in the other trauma category included 2 birds with a leg dangle, 4 leg fractures, 6 fence and vehicle collisions, and 3 instances of lameness. The bird from the miscellaneous conditions category lost its foot below the tarsal joint and subsequently went missing shortly thereafter. No mortalities were associated with deformities; however, such an association would be unlikely to be observed. Birds were only released with deformities considered unlikely to influence survival. Except for captures to repair fractured legs, no serious capture or handling injuries occurred. Three birds died during hospitalization to repair or treat leg fractures. Two died from complications of anesthesia and 1 suffocated from aspiration of corn. The remaining birds either had injuries not considered related with mortality ($n = 73$,

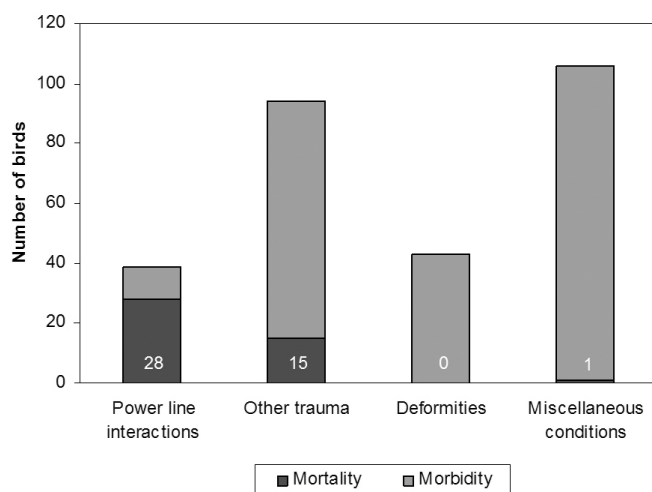


Figure 5. Injury-related morbidity and mortality in whooping cranes in central Florida, 1992-2007.

50% of injured birds, 24% of total population) or were still alive in 2007 ($n = 31$, 21% of injured birds, 10% of total population). Birds with injury were found to survive longer (mean = 47.2 months) than birds with no previously recorded injury (mean = 30.7 months) ($P < 0.001$). We found no indication that source ($P > 0.05$) or rearing method ($P > 0.05$) predisposed birds to leg problems or power line interactions.

DISCUSSION

Although leg problems were common in the Florida resident population, only a few types of problems appeared to be significant to the health and survival of the birds. Forty-four birds were believed to die from leg-associated problems or power line interactions. Power lines were the most common cause for these deaths. Other manmade hazards associated with whooping crane mortality included fences, monofilament line, vehicles, cow feeders and golf balls. Many of these hazards are associated with birds living in or close to urban areas. Power lines injure and kill other crane species and other large birds (Crivelli et al. 1988, Cochrane et al. 1991, Janss and Ferrer 2000, Sundar and Choudhury 2005) as well as whooping cranes in other wild flocks (Stehn and Wassenich 2008).

The greater mortality of males, especially older males, from power line collision may be due to a male flying ahead of the female and hitting the line first, alerting the female, or cushioning the blow; however,

there have been 2 cases where 2 and 3 birds died in a single event.

Frequent mortality from particular power lines appears to occur when a line is located between foraging and roosting sites. Low light and fog conditions between these sites may contribute to the reasons that the lines are struck. Poor weather conditions affect the bird's ability to see and react to an imminent power line collision (Crivelli et al. 1988, Cochrane et al. 1991, Savereno et al. 1996, Stehn and Wassenich 2008). The consideration of power line presence when choosing release sites is made difficult by the rarity of power line-free areas, the rapid increase in new power lines, and the inability to predict which roosting and foraging areas will be used by the birds after release since birds frequently moved large distances from release sites.

To combat the problem of power line interactions, the Florida Fish and Wildlife Conservation Commission worked with a local power company to place markers (Firefly Bird Flappers®, PR Technologies, Portland, OR) on 8 km of the power lines most frequently encountered. Other studies concur that marking power lines reduce the number of mortalities (Morkill and Anderson 1991, Alonso et al. 1994, Stehn and Wassenich 2008). Because we found 50% of power line interactions involved the transmitter, we began deploying a new style of transmitter in September 2006. The new transmitter has an angled leading edge, unlike the blunt edge of the old transmitter. The purpose of the new design was to allow a transmitter to glance off the power line as the bird flies over instead of catching on the line. By the end of 2007, 13 whooping cranes had been fitted with the modified transmitters. During the 15 months since using the new transmitter design, 3 power line interactions have been recorded, all in birds that had not yet been fitted with a new streamlined transmitter.

Contrary to expectation, whooping cranes with injuries survived longer than birds with no injuries. Since most mortalities were caused by trauma it does seem reasonable that birds surviving less severe traumatic events might survive longer on average than birds that die from more severe traumatic events with no prior observed leg problem. The source and rearing method of a bird have no bearing on whether or not a bird will become injured.

We found no clear evidence that a specific type of leg deformity influenced survival or reproductive success. Limb deformities have been noted in husbandry of

captive cranes in general (Olsen and Langenberg 1996) and for whooping cranes specifically (Kelley and Hartup 2008), and are thought to be the result of dietary or exercise problems. Changes in diet and increased exercise appear to have resolved some of these problems (Kelley and Hartup 2008). Although we never recorded the death of a crane due to leg or foot malformation, the documentation of such an occurrence would be difficult.

Capture and handling injury was limited to minor wounds and toenail loss in a few out of >800 handling events. By avoiding the handling of young, growing, birds, which seem much more susceptible to leg injury, leg injuries were kept to a minimum in this study. Wild-hatched chicks were not captured or handled until they were strong fliers (>4 months of age). In our study it was not clear that intervention by hospitalizing a bird with a fractured leg resulted in the best outcome. Intervention for birds with fractured legs never resulted in a releasable bird, whereas one left in the wild went on to successfully reproduce. Because the chances for a hospitalized bird to be released back in the wild are low, we recommend careful consideration for leaving a bird with a fractured leg in the field if the conditions warrant any chance for recovery on its own.

Naturally acquired injuries by wild birds were rare and less likely to be discovered, whereas interactions with human-made objects were common enough to have population level impacts. These findings corroborate those found earlier for Florida cranes (Folk et al. 2001).

Chondromas, possibly due to a virus, have occasionally been seen in sandhill cranes (*Grus canadensis*) in Florida and can be severe enough to be life threatening (Forrester and Spalding 2003). Both of the lesions on whooping cranes were small and 1 regressed with time.

A problem requiring management is the entanglement of legs by monofilament line and bill entrapment by artificial objects. Although the second is not a leg problem, both require that the bird be captured to prevent death or, in the case of monofilament line entanglement, the loss of a foot. Monofilament line reclamation and education projects at popular recreation sites, close observation of birds, and capture and removal can all help to prevent mortality or limb loss.

In summary, we found that leg problems in wild whooping cranes were common, and generally those of significance involved man-made objects such as power lines, fences, vehicles, and monofilament line. Birds that

were able to survive an injury went on to live longer than birds with no previously observed injury. Power line interactions were the most common cause of mortality and injury for birds with leg injuries and power line interactions. Line markers and transmitter design changes were instituted and further observations will be necessary to determine if mortality is reduced. Intervention to remove monofilament line was always successful; however, intervention to resolve a fractured leg was not. Capture or handling injuries were minimal and no deaths were associated with those injuries except when birds were hospitalized for fractured legs. Leg deformities noted at the arrival or pre-release examinations did not significantly influence survival or reproduction. Where and how the birds were reared also did not significantly affect incurring any future injuries.

ACKNOWLEDGMENTS

We thank J. Schmidt, T. Miller, K. Sullivan, J. Parker, S. Schwikert, J. Rodgers, S. Nesbitt, K. Candelora, S. Hatcher, and S. Baynes for their expert assistance with captures. We thank the many landowners for access to their properties. Funding for this work was supported in part by the U.S. Fish and Wildlife Service via Cooperative Agreement No. 401814-J-035.

LITERATURE CITED

- Alonso, J. C., J. A. Alonso, R. Mufioz-Pulido. 1994. Mitigation of bird collisions with transmission lines through groundwire marking. *Biological Conservation* 67:129-134.
- Canadian Wildlife Service [CWS] and U.S. Fish and Wildlife Service [USFWS]. 2007. International recovery plan for the whooping crane. Recovery of Nationally Endangered Wildlife (RENEW), Ottawa, Ontario, Canada, and U.S. Fish and Wildlife Service, Albuquerque, New Mexico, USA.
- Cochrane, K. L., R. J. M. Crawford, and F. Kriel. 1991. Tern mortality caused by collision with a cable at Table Bay, Cape Town, South Africa in 1989. *Colonial Waterbirds* 14:63-65.
- Crivelli, A. J., H. Jerrentrup, and T. Mitchey. 1988. Electric power lines: a cause of mortality in *Pelecanus crispus* Bruch, a world endangered bird species, in Porto-Lago, Greece. *Colonial Waterbirds* 11:301-305.
- Folk, M. J., S. A. Nesbitt, and M. G. Spalding. 2001. Interactions of sandhill cranes and whooping cranes with foreign objects in Florida. *Proceedings of the North American Crane Workshop* 8:195-197.

- Folk, M. J., S. A. Nesbitt, S. T. Schwikert, K. A. Sullivan, T. M. Miller, S. B. Baynes, and J. M. Parker. 2005. Techniques employed to capture whooping cranes in central Florida. *Proceedings of the North American Crane Workshop* 9:141-144.
- Forrester, D. J., and M. G. Spalding. 2003. Cranes. Pages 702-740 in *Parasites and diseases of wild birds in Florida*. University Press of Florida, Gainesville, Florida, USA.
- Janss, G. F. E. and M. Ferrer. 2000. Common crane and great bustard collision with power lines: collision rate and risk exposure. *Wildlife Society Bulletin* 28:675-680.
- Kelley, C., and B. K. Hartup. 2008. Risk factors associated with developmental limb abnormalities in captive whooping cranes. *Proceedings of the North American Crane Workshop* 10:119-124.
- Morkill, A. E., and S. H. Anderson. 1991. Effectiveness of marking powerlines to reduce sandhill crane collisions. *Wildlife Society Bulletin* 19: 442-449.
- Nagendran, M., R. P. Urbanek, and D. H. Ellis. 1996. Special techniques, part D: reintroduction techniques. Pages 231-240 in D. H. Ellis, G. F. Gee, and C. M. Mirande, editors. *Cranes: their biology, husbandry, and conservation*. National Biological Service, Washington D.C., and International Crane Foundation, Baraboo, Wisconsin, USA.
- Nesbitt, S. A., M. J. Folk, M. G. Spalding, J. A. Schmidt, S. T. Schwikert, J. M. Nicolich, M. Wellington, and J. C. Lewis. 1997. An experimental release of whooping cranes in Florida—the first three years. *Proceedings of the North American Crane Workshop* 7:79-85.
- Olsen, G. H., and J. A. Langenberg. 1996. Veterinary techniques for rearing crane chicks. Pages 100-103 in D. H. Ellis, G. F. Gee, and C. M. Mirande, editors. *Cranes: their biology, husbandry, and conservation*. National Biological Service, Washington D.C., and International Crane Foundation, Baraboo, Wisconsin, USA.
- Savereno, A. J., L. A. Savereno, R. Boettcher, and S. M. Haig. 1996. Avian behavior and mortality at power lines in coastal South Carolina. *Wildlife Society Bulletin* 24:636-648.
- Spalding, M. G., M. J. Folk, S. A. Nesbitt, and R. Kiltie. 2010. Reproductive health of the Florida flock of introduced whooping cranes. *Proceedings of the North American Crane Workshop* 11:142-155.
- Stehn, T. V., and T. Wassenich. 2008. Whooping crane collisions with power lines: an issue paper. *Proceedings of the North American Crane Workshop* 10:25-36.
- Sundar, K. S. G., and B. C. Choudhury. 2005. Mortality of sarus cranes (*Grus antigone*) due to electricity wires in Uttar Pradesh, India. *Environmental Conservation* 32:260-269.
- Wellington, M., A. Burke, J. M. Nicolich, and K. O'Malley. 1996. Chick rearing. Pages 77-104 in D. H. Ellis, G. F. Gee, and C. M. Mirande, editors. *Cranes: their biology, husbandry, and conservation*. National Biological Service, Washington D.C., and International Crane Foundation, Baraboo, Wisconsin, USA.